

# Autologous Fibroblasts for Treatment of Facial Rhytids and Dermal Depressions

## A Pilot Study

Deborah Watson, MD; Gregory S. Keller, MD; Victor Lacombe, MD; Peter B. Fodor, MD; Jeffrey Rawnsley, MD; Gary P. Lask, MD

**Objective:** To assess effectiveness of intradermal injections of autologous fibroblasts for the treatment of facial rhytids and dermal depressions.

**Design:** Six-month prospective pilot study. Photographs and silicone molds were taken of a prominent rhytid or dermal depression from each patient prior to treatment and at 6 months after treatment.

**Setting:** Specialty clinic in academic medical center.

**Patients:** Ten adults (age range, 24-69 years) who each exhibited a prominent rhytid or depressed facial scar.

**Intervention:** A 3-mm postauricular skin biopsy specimen from each participant was sent to Isologen Technologies, Inc, laboratories, where a fibroblast cell line was developed. Three injection sessions were performed at 2-week intervals; target areas were the study site as well as behind the ear.

**Main Outcome Measures:** Subjective improvement scores were obtained by each patient and 2 clinicians at every follow-up visit. Skin surface topographical features were evaluated with optical profilometry by comparing silicone molds before and after injection. Histological analysis was performed on a biopsy specimen of the postauricular injection site.

**Results:** Nine of 10 patients noted a 60% to 100% improvement with the treatment; clinicians made similar observations. Size reduction of 10% up to 85% of the study site was demonstrated by optical profilometry for every patient. Microscopically, there was evidence of increased thickness and density of dermal-layer collagen.

**Conclusions:** Intradermal injection of autologous fibroblasts may be an effective treatment option for facial rhytids and depressed scars.

*Arch Facial Plast Surg. 1999;1:165-170*

**I**NJECTABLE COLLAGEN has become a popular method for correcting soft tissue contour defects since its introduction in 1977.<sup>1</sup> It has been used to fill superficial wrinkles around the eyes and lip and deeper furrows often seen in the forehead, glabella, or nasolabial regions. Satisfying results have been observed when used to correct acne and chickenpox depressions, iatrogenic-traumatic scars, and areas of dermal atrophy.

Purified bovine collagen is available as Zyderm I (35 mg/mL of collagen), Zyderm II (65 mg/mL of collagen), and Zyplast (35 mg/mL; collagen cross-linked with glutaral) (Isologen Technologies, Inc, Paramus, NJ). Unfortunately, 1% to 6% of healthy patients receiving collagen injections experience a localized hypersensitivity reaction.<sup>2-4</sup> Usually this manifests as temporary erythema, pruritus, induration, and swelling. Granulomatous foreign body reactions have been reported by

Overholt et al<sup>5</sup> and Moscana et al.<sup>6</sup> Others<sup>2,7</sup> have documented the development of erythematous nodules at the injection sites, which can take up to 3 years to subside. Overholt et al<sup>5</sup> indicated that the source of the allergic response may be a reaction to bovine antigen. Because of its heterogeneous nature, preliminary tolerance tests to the collagen implant are necessary.<sup>8-12</sup>

The use of collagen is only a temporary corrective measure. Zyderm I is rapidly digested by tissue collagenases and is resorbed in several weeks. The higher concentration of collagen in Zyderm II delays resorption time to within 3 months.<sup>12</sup> Zyplast has some advantage with its content of glutaral but still eventually disappears.

Soft tissue augmentation with autologous material theoretically circumvents problems with resorption and allergic reactions. Fat, although autologous, tends to have shortcomings as an injectable filler. Surgical harvesting and processing are re-

*From the Divisions of Head and Neck Surgery (Drs Watson, Keller, Lacombe, and Rawnsley), Plastic Surgery (Dr Fodor), and Dermatology (Dr Lask), University of California, Los Angeles. Dr Watson is now with the Division of Head and Neck Surgery, University of California, San Diego.*

## PATIENTS AND METHODS

Ten healthy adult patients (age range, 24-69 years) seeking improvement of facial rhytids or depressed facial scars were referred to the study clinicians by the dermatology or facial plastic surgery clinics in our institution. Any history of autoimmune disease, chronic skin disorders, disseminated cancer, or organ transplantation excluded a participant from the study. Each patient presented with prominent glabellar lines, perioral rhytids, nasolabial folds, or depressed facial scars. A study site was chosen, and its location was measured and recorded with respect to a nearby facial anatomical landmark (eg, lateral canthus, oral commissure). All subjects were informed of the goals and methods of the study, the necessity for reliable follow-up, and the potential risks associated with the use of injectable materials prior to signing consent forms. Patients were also requested to refrain from any skin resurfacing-lifting procedure for the duration of the study.

Pretreatment photographs and a pair of identical silicone molds were taken of each participant's study site. Acquiring silicone molds of the skin defect began with thorough cleaning of the target surface with 70% isopropyl alcohol pads. A foam self-adhesive ring with a diameter of 19 mm (CuDerm Corp, Dallas, Tex) was carefully placed over the study site so as not to distort the skin topography. Silicone elastomer (Silflo Silastic) replicating resin premixed with catalyst (CuDerm Corp) was spread over the study site without applying pressure; an intentional 2- to 3-mm overlap was made on top of the ring. The resin polymerized in less than 3 minutes, at which time the silicone mold together with the ring was gently peeled off the skin surface and labeled.

A 3- to 4-mm punch biopsy specimen was taken from the postauricular crease for every subject using 1% lidocaine with 1:100 000 epinephrine for local anesthesia. The skin defect was closed with a single 5-0 chromic suture. The specimen was sent in a sterile, labeled transport media tube on ice and in a thermos by overnight delivery to the Isologen laboratory. The cells were then expanded by proprietary tissue culture techniques during the next 6 weeks.<sup>17</sup> At this time, a 0.1-mL intradermal test injection of autologous cells was performed using a 30-gauge needle on the volar aspect of the forearm for each participant. The patient was instructed to record any evidence of an allergic skin reaction.

By the second week, a sterile 2-mL vial containing 1.3 to 1.5 mL of autologous fibroblasts suspended in 5% dextrose injection (5% dextrose-lactated Ringer's solution;

Baxter-Allegiance, Round Lake, Ill) was sent on ice in a thermos via overnight delivery to the clinic for each patient. To ensure optimal viability of the cells, therapeutic injections were always scheduled within 24 hours of shipping.<sup>16</sup> No preparation of the injectable material was required. The cells were loaded into a 3-mL syringe and injected with a 2.2-cm-long 30-gauge needle. Prior to injection, the target skin surface was cleansed thoroughly with 70% isopropyl alcohol pads. Local anesthesia was preferred by most patients and consisted of nerve blocks, topical injections of 1% lidocaine, or surface application of a mixture of 2.5 % lidocaine and 2.5 % prilocaine cream. When topical injections were used, care was taken to avoid distorting the skin defect. The anesthetic was placed clear of the target site.

The injection technique required multiple passes into the upper and middle dermal layers with the bevel of the needle pointed down. It was necessary to fill in the skin defect with the injection and also to attempt to create blanching and tension on the skin surface during the process. This ensured a maximal effect in the dermis each time (**Figure 1**). All patients received injections to the study site, a designated area behind the ear, and facial areas of their choice. Ice packs were administered to the treated areas for the next 2 hours.

Therapeutic injection sessions were repeated at 2- to 3-week intervals for a total of 3 injection sessions for each participant. Follow-up visits were made every 2 to 3 months from the date of the last injection session. At each visit, the participant and 2 clinical observers (one of whom was D.W.) were shown pretreatment photographs. Each individual was asked to score any improvement using a 0% to 100% scale.

At the 6-month follow-up visit, photographs of the site after the treatment and silicone molds were acquired. In addition, a 3- to 4-mm punch biopsy specimen was taken behind the ear at the site that had received all 3 injections. This specimen was placed in formalin and processed for microscopic analysis using hematoxylin-eosin staining.

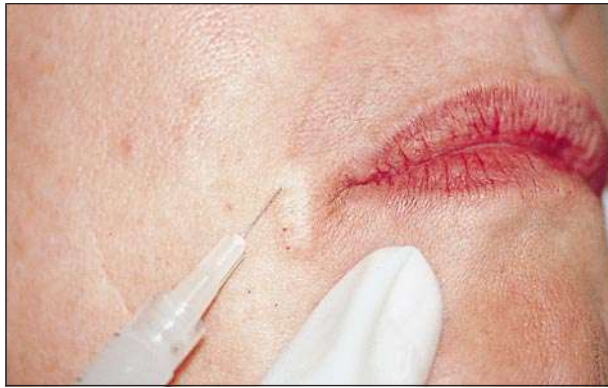
Appropriately labeled silicone molds of each participant before and after the injection were sent to the Skin Study Center (Broomall, Pa), where specific computerized optical profilometry measurement capability is available. The application involves a computerized digital image-processing system with specially designed image-processing hardware and software. A fiberoptic illuminator at a fixed angle is used to enhance the surface features of the silicone mold so that an image profile can be created. The image is then digitized into a pixel matrix to elicit numeric data that corresponded to microtopographic features on the silicone mold.<sup>18</sup>

quired prior to its use, results are variable, and reapplication is necessary because of its tendency to undergo resorption.<sup>13,14</sup>

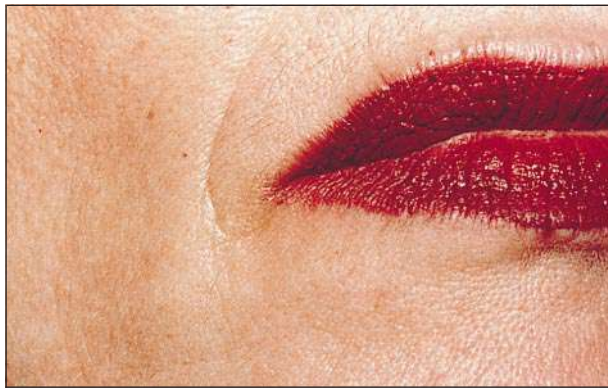Other autologous injectable materials include a dispersion of intact autologous collagen fibers that have been derived from the patient's dermal layer (Collagenesis Inc, Beverly, Mass). One-year results demonstrating more than 75% correction after at least 3 injections have been reported.<sup>15</sup> Unfortunately, this application has limited yield. To obtain 1 cm<sup>2</sup> of dispersed collagen fibers, up to 19.5 cm<sup>2</sup> of skin is required for processing. Repeated applications to attain full correction necessitate additional skin excision.

Ideal autologous, injectable material should provide long-term correction, require negligible surgery for initial tissue harvest, and have unlimited yield without the need for additional tissue harvest. The soft tissue augmentation system that aligns with these principles is available from Isologen Technologies, Inc. The system requires a small skin sample from the patient to develop an autologous fibroblast cell line. Living cells are then injected back into the patient to correct skin contour defects. Once reintroduced into the dermis, the fibroblasts participate in a long-term protein repair process that helps to sustain the corrective effect.

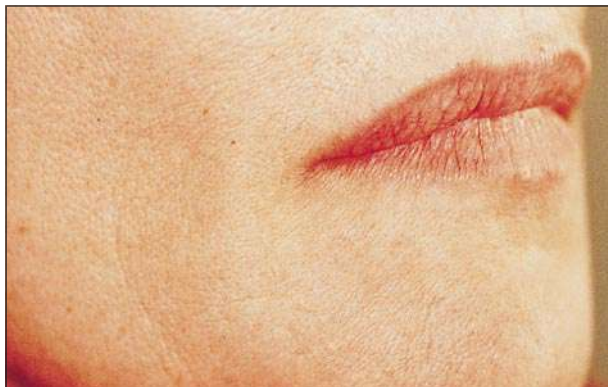Isologen Technologies, Inc, has made this system available for clinical use during the last 3 years. Long-



**Figure 1.** Injection technique, using a 2.2-cm-long 30-gauge needle, involved placing the cells into the upper and middle dermis. Blanching and surface tension on the skin is observed during defect filling.



**Figure 2.** Pretreatment nasolabial fold of patient 1.

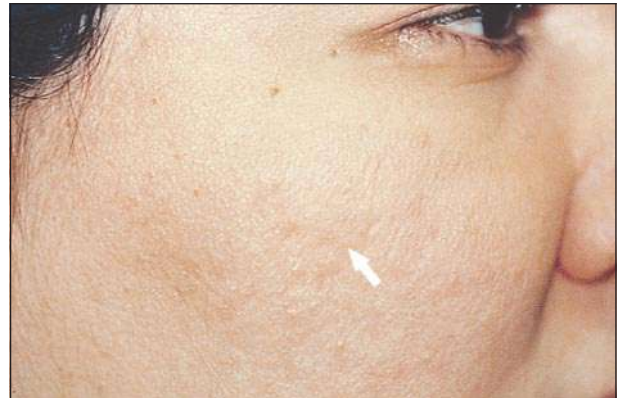

**Figure 3.** Nasolabial fold of patient after treatment at 6 months.

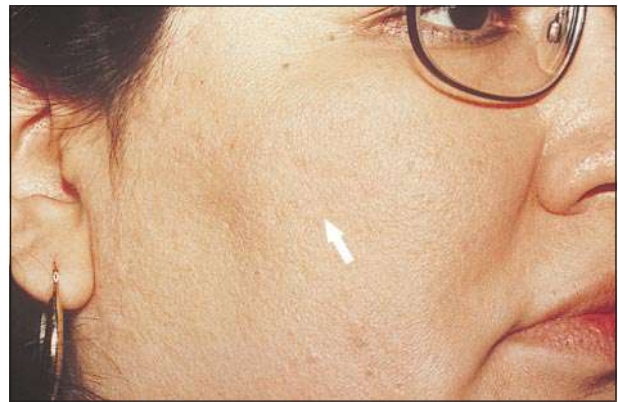
term correction of more than 2.5 years and absence of allergic adverse effects (erythema, pruritus, or swelling) have been reported.<sup>16</sup> This pilot study was undertaken to assess the effectiveness of the Isologen system as well as to substantiate these subjective findings with objective data.

## RESULTS

Photographs before and after the injection are included for patient 1, who demonstrated correction of nasolabial folds, and for patient 4, who revealed improvement of an acne scar over the malar region (**Figure 2**, **Figure 3**, **Figure 4**, and **Figure 5**). There were no



**Figure 4.** Pretreatment acne scar of patient 4 (arrow).



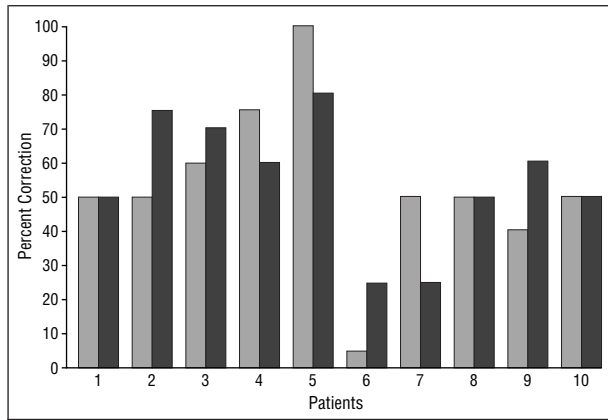
**Figure 5.** Acne scar after treatment of patient 4 at 6 months (arrow).

reports of infection or diffuse allergic reactions; however, patient 1 experienced self-limiting erythema at her injection sites that persisted for 3 days without sequelae.

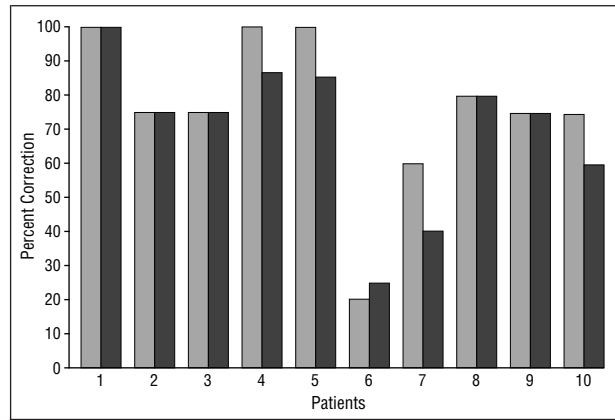
Few of the participants noticed subjective improvement after the second injection session, but most reported changes subsequent to the third injection session. By the 3-month follow-up visit, 9 of the 10 patients noted 40% to 100% subjective improvement; patient 6 described only a 5% improvement. The scores given by the 2 clinicians (one of whom was D.W.) were averaged for each subject and these demonstrated a 50% to 80% subjective improvement for 8 of 10 patients. A score of 25% was given by the clinicians for patients 6 and 7 (**Figure 6**). The patient scores correlated well with those given by the clinicians (2-tailed  $t$  test,  $r = 0.92$ ;  $P < .01$ ).

Subjective improvement scores continued to increase by the 6-month follow-up visit. Nine of 10 patients reported 60% to 100% subjective improvement, while patient 6 submitted a score of 20% improvement. The averaged improvement scores by the clinicians ranged from 60% to 100% for 8 of 10 subjects. Again, the lowest scores, 25% and 40%, were assigned to patients 6 and 7, respectively (**Figure 7**). The lowest scores of subjective improvement were consistently assigned to patients 6 and 7 during all follow-up visits. These 2 participants were the older individuals in our study (ages, 69 and 59 years, respectively).

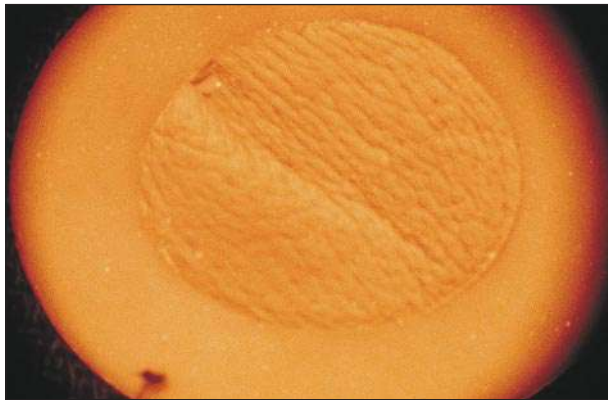
Both pairs of silicone molds taken from each patient before treatment and 6 months after treatment were



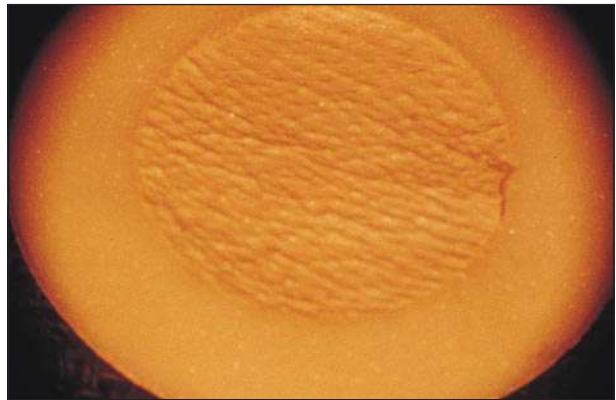
**Figure 6.** Subjective improvement scores at 3 months. Light-shaded bars indicate patient scores and dark-shaded bars represent the averaged scores of the 2 clinicians.



**Figure 7.** Subjective improvement scores at 6 months. Light-shaded bars indicate patient scores and dark-shaded bars represent the averaged scores of the 2 clinicians.



**Figure 8.** Representation (1:1) of a pretreatment silicone mold. Surface detail demonstrates the negative impression of a skin rhytid. Diameter of replica is 19 mm.



**Figure 9.** Representation (1:1) of a silicone mold after treatment taken at 6 months. Note the reduction in shadow effect due to the correction of the rhytid.

sent to the Skin Study Center. The technicians at the center selected 1 replica of each pair with the greatest amount of skin topographic detail for optical profilometry measurements. For the purposes of the study, the portion of data analyzed involved the percentage of replica surface area covered by a shadow that was cast by light against the skin defect. The shadow area percentages of pretreatment replicas were compared with those of molds made after treatment. **Figure 8** and **Figure 9** represent typical silicone replicas before and after treatment, respectively.

The percent reduction of the replica shadow area was determined after comparing the values before and after treatment. **Figure 10** illustrates the reduction percentages for all patients. Results from every patient revealed shadow-area reduction, ie, all study sites became more shallow. The least demonstrable effect is noted again with patients 6 and 7.

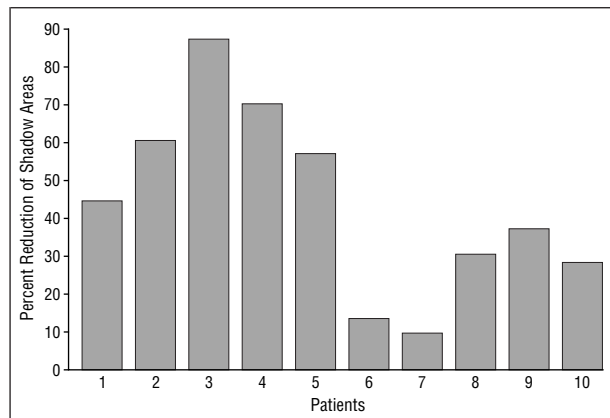
A positive correlation was found between the objective measurement values and the subjective improvement scores given by the clinicians (one of whom was D.W.) (2-tailed *t* test,  $r = 0.67$ ;  $P < .05$ ). However, a significant correlation was not present when the objective measurements were analyzed with patient subjective improvement scores.

The histopathological features of the injected postauricular biopsy specimens were compared with those

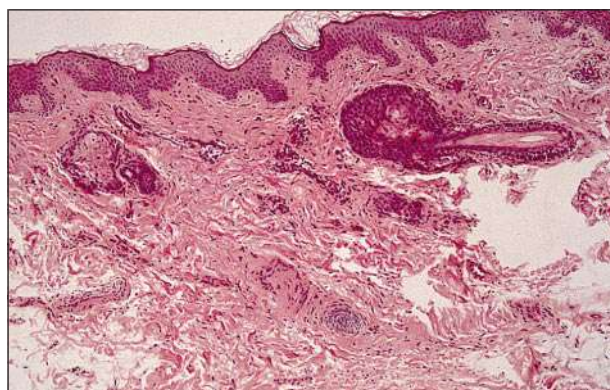
of healthy skin behind the ear. **Figure 11** represents normal epidermal and dermal layers (original magnification  $\times 100$ ) and **Figure 12** is a photomicrograph of an injected area at the identical magnification. The treated skin specimen demonstrated a denser and thicker layer of collagen in the dermal region, absence of any inflammatory reaction, and viable fibroblasts throughout.

#### COMMENT

Treatment of superficial facial rhytids and small scar depressions with injectable materials is an alternative to implant products that are surgically inserted. The injection technique, however, offers precise control of quantity delivered and depth of placement. Shortcomings with current injectable materials include significant surgical tissue harvest for material processing, reported inflammatory or immunologic reactions, and eventual resorption, thereby requiring numerous reapplications if continued correction is desired. Any autologous material that is applied by injection technique does not require significant surgical harvest, provides limitless yield, demonstrates long-term correction by clinical reports, and represents the ideal augmentation material for facial rhytids and dermal depressions. Our pilot study suggests that the Isolagen system fulfilled these objectives.



**Figure 10.** Percent reduction of the silicone replica shadow area for each patient was determined after comparing optical profilometry measurements before and after treatment.

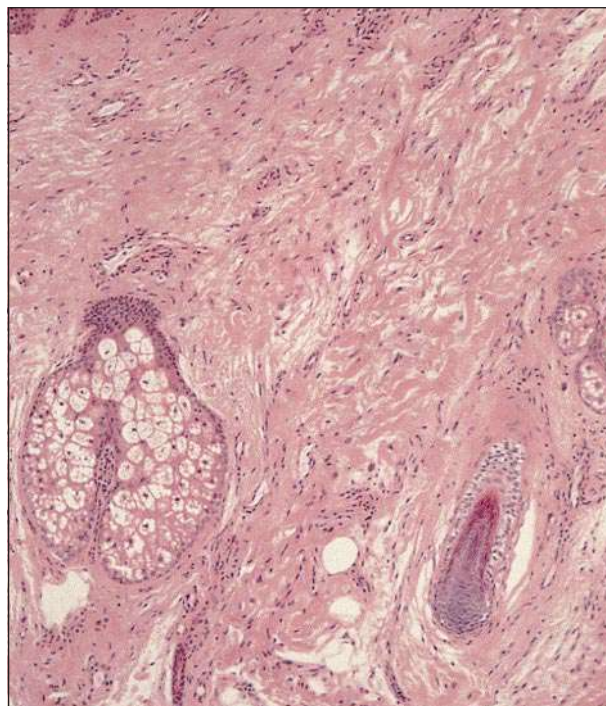


**Figure 11.** Biopsy specimen of untreated postauricular skin (hematoxylin-eosin, original magnification  $\times 100$ ).

Three injection sessions appeared to provide an adequate density of fibroblasts to maintain correction beyond 6 months for most patients in our study. It is uncertain if patients 6 and 7, who demonstrated the least amount of correction, would have had better success with a total of 4 or 5 injections. The age of these 2 participants ( $>59$  years) could be a significant factor that affected the biological activity of the injected fibroblasts, but it is difficult to draw any conclusions within our small study group. Interestingly, poor results with patients older than 65 years have been reported by other clinicians using the Isologen system.<sup>16</sup>

A unique feature of the Isologen system is its ability to effect continual and gradual improvement of the skin surface contour for months after the injection sessions have been completed. There have not been any reports of nodular hypertrophy or keloid formation since the initial use of Isologen more than 3 years ago (oral communication, Gregory Keller, MD, University of California, Los Angeles [UCLA] Medical Center, July 1997; oral communication, William Boss, Jr, MD, Hackensack University Medical Center, Hackensack, NJ, April 1998). Cell-to-cell contact inhibition is postulated to play a role with regulating the synthesis of collagen or the replication of fibroblasts.

Subjective improvement scores are useful indicators of changes with the study site. We found that scores from the participants strongly correlated with those that



**Figure 12.** Six-month biopsy specimen of injected postauricular skin (hematoxylin-eosin, original magnification  $\times 100$ ). Note the increased density and thickness of collagen in the dermal region as compared with Figure 11.

were averaged from the 2 clinical observers (one of whom was D.W.). Although the data from the optical profilometry measurements correlated strongly with the subjective improvement scores from the clinicians, the effect was not as pronounced with the patient scores. Perhaps greater objectivity by clinical observers provided more accurate scoring. Moreover, results from optical profilometry were not as dramatic as the subjective improvement scores. A possible explanation for these more subtle findings could be attributed to the viscosity of the silicone resin. The moderately high viscosity of the resin may have impeded the filling of the central crevice of a rhytid; therefore, a more "shallow" mold was taken. Otherwise, the silicone replicas, once polymerized, reliably maintained their contours for measurement and indefinite storage.<sup>19</sup>

With respect to the histological findings, fibroblasts appeared to be incorporated into the dermal architecture and either began nascent production of collagen or stimulated synthesis from the native cells, subsequently, creating the thicker collagen layer.

Overall, there was a high index of participant satisfaction in this study. Patients and clinical observers did not report any evidence of skin infection. Only 1 subject noted prolonged erythema at her injection sites; it is unclear whether this might have been a reaction to the use of lidocaine as the anesthetic.

Follow-up beyond 6 months is of great interest to us. A larger study at our institution is in progress, involving 38 participants with follow-up ranging from 12 to 24 months. The Isologen system holds numerous advantages and negligible risks. Further evidence of its long-term corrective ability would provide a significant contribution to the practice of soft tissue augmentation.

Accepted for publication May 17, 1999.

Presented at the fall meeting of the American Academy of Facial Plastic & Reconstructive Surgery, San Antonio, Tex, September 11, 1998.

We thank Isologen Technologies, Inc, for processing the skin biopsy specimens and providing the fibroblast injections; Mary Jo Grove, MSc, Skin Study Center, for the optical profilometry measurements; Minu K. Patel, MSc, University of Illinois at Chicago, for the statistical analysis; Scott Nelson, MD, UCLA Department of Pathology, for his interpretive assistance with the histological studies; and Sassan Alavi, MD, and Kay Durairaj, MD, UCLA Division of Head and Neck Surgery, for their assistance with patient follow-up visits.

Corresponding author: Deborah Watson, MD, 4991 Concannon Ct, San Diego, CA 92130.

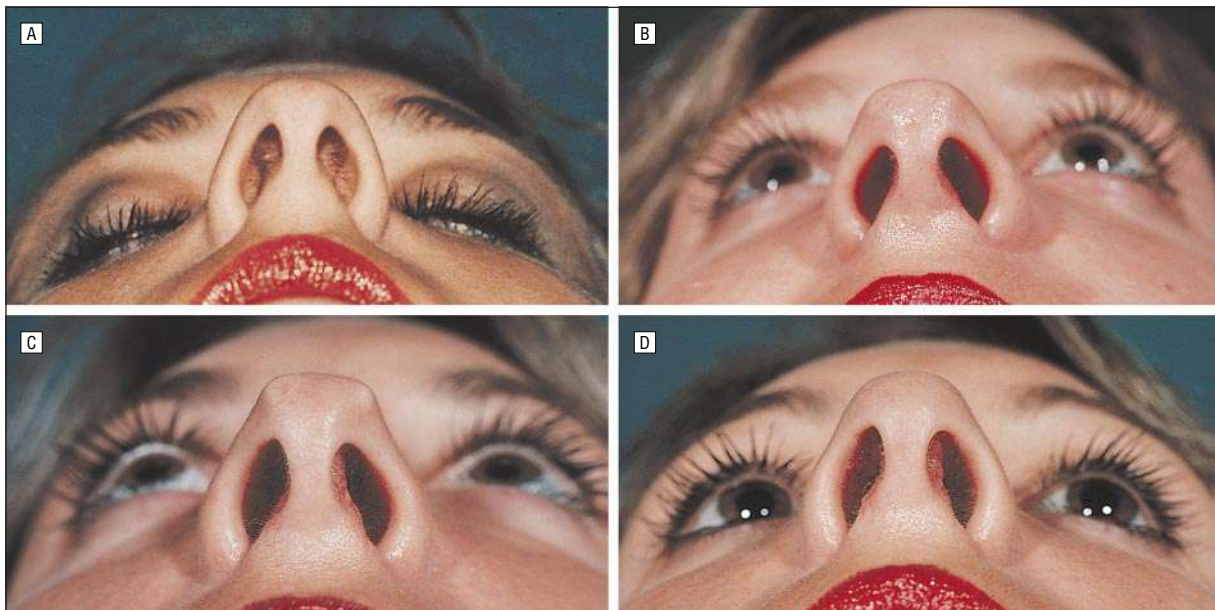
Reprints: Gregory Keller, MD, 2323 De La Vina, Suite 104, Santa Barbara, CA 93105 (e-mail: faclftr@aol.com).

## REFERENCES

1. Knapp TR, Kaplan EN, Daniels JR. Injectable collagen for soft-tissue augmentation. *Plast Reconstr Surg.* 1977;60:398-405.
2. Kaplan EN, Falces E, Tolleth H. Clinical utilization of injectable collagen. *Ann Plast Surg.* 1983;10:437-451.
3. Cooperman LS, Mackinnon V, Bechler G, Pharriss BB. Injectable collagen: a six year clinical investigation. *Aesthetic Plast Surg.* 1985;9:145-151.
4. De Lusto F, Fries J, Kang A, et al. Immunity to injectable collagen and autoimmune disease: a summary of current understanding. *J Dermatol Surg Oncol.* 1988;14(suppl 1):57-65.
5. Overholt MA, Tscher JA, Font RL. Granulomatous reaction to collagen implant: light and electron microscopic observations. *Cutis.* 1993;51:95-98.
6. Moscana RR, Bergman RB, Friedman-Birnbaum R. An unusual late reaction to Zyderm I injections: a challenge for treatment. *Plast Reconstr Surg.* 1993;92:331-334.
7. Clark DP, Hanke CW, Swanson NA. Dermal implants: safety of products injected for soft tissue augmentation. *J Am Acad Dermatol.* 1989;21:992-998.
8. Baral J. Collagen skin testing. *J Dermatol Surg Oncol.* 1990;16:70.
9. Barr RJ, Stegman SJ. Delayed skin testing reaction to injectable collagen implant (Zyderm). *J Am Acad Dermatol.* 1984;10:652-658.
10. Colton JJ, Tashjian RC. Injectable collagen materials in facial plastic surgery. *Facial Plast Surg Clin North Am.* 1994;2:77-87.
11. Elson ML. The role of skin testing in the use of collagen injectable materials. *J Dermatol Surg Oncol.* 1989;15:301-303.
12. Spira M, Rosen T. Injectable soft tissue substitutes. *Clin Plast Surg.* 1993;20:181-188.
13. Illouz YG. Present results of fat injection. *Aesthetic Plast Surg.* 1988;12:175-181.
14. Chajchir A. Fat-grafting injection for soft-tissue augmentation. *Plast Reconstr Surg.* 1989;84:921-934.
15. DeVore DP, Kelman CD, Fagien S, Casson P. Autologen: autologous, injectable dermal collagen. In: Bosniak S, ed. *Principles and Practices of Ophthalmic Plastic and Reconstructive Surgery.* Philadelphia, Pa: WB Saunders Co; 1996:670-675.
16. Boss WK, Marko O. Isologen. In: Klein AW, ed. *Tissue Augmentation in Clinical Practice.* New York, NY: Marcel Dekker Inc; 1998:335-347.
17. Boss WK, inventor; Isologen Technologies Inc, assignee. Use of autologous dermal fibroblasts for the repair of skin and soft tissue defects. US patent 5 660 850. August 26, 1997.
18. Grove GL, Grove MJ, Leyden JJ. Optical profilometry: an objective method for quantification of facial wrinkles. *J Am Acad Dermatol.* 1989;21:631-637.
19. Gormley DE. Three-dimensional optical micrometric analysis of casts of cutaneous surfaces. *Bioeng Skin.* 1985;1:81-92.

## Correction

**Error in Figure Orientation.** In the original article titled, "Nasal Tip Bossae in Rhinoplasty: Etiology, Predisposing Factors, and Management Techniques," published in the April-June 1999 issue of the ARCHIVES (1999;1:83-89), **Figure 5**, C and D, on page 88 were transposed incorrectly during processing for publication. Figure 5 is reprinted correctly here.



**Figure 5.** Patient who underwent vertical dome division without suturing the medial elements together who developed bilateral bossae during a 2-year period. Revised using delivery technique, shave excision, and suturing of medial crura together. Preoperative (A), 2-month postoperative (B), 2-year postoperative (C), and 6-month postrevision (D) views.